

The Clinical Efficacy and Statistical Evaluation of INTRAcel Treatment

Takashi Takahashi, M.D.

Dermatologist

Takahashi Clinic

Shibuya, Tokyo, Japan

Background:

Minimally invasive Fractional Radiofrequency Microneedles (FRM) device is recently introduced. The device gives selective heating in the dermis using bipolar RF (or monopolar RF) through microneedles. This study is to demonstrate clinical improvement following FRM.

Methods:

60 subjects with scar, facial laxity and large pore were enrolled. 60 patients were treated with a minimally-invasive FRM device (INTRAcel). Bipolar RF energy was delivered through 49 micro-needle electrodes deployed into the reticular dermis from the papillary dermis vertically to the skin surface. Only subjects consenting to longitudinal follow-up during the study were enrolled to observe the improvement as time went by.

Results:

As the result of 3 months follow-up, all patients did not have any problems during the period and any adverse events or complications weren't observed. Patient satisfaction was high with 83.3%. Self-assessment of clinical outcome showed moderate to significant improvement in skin laxity, scar and pore.

Conclusion:

Bipolar RF treatment makes deep dermal fractional heating in targeted deeper dermis. Clinical improvement by FRM treatment is

related to collagen and elastin fiber which are generated by wound healing process.

These results suggest Fractional Radiofrequency Microneedles treatment may become an important option for the treatment of facial skin laxity and scars.

INTRODUCTION

Previous generation ASR (Ablative Skin Resurfacing) laser devices were effective, but many of them could not avoid the problems of long down time and patient pain. On the contrary, NAR (Non-ablative Skin Rejuvenation) laser devices reduced pain and adverse effects, but these devices could not make dramatic effects. In the middle of 2000s, fractional technology opened new generation overcoming previous problems. But the fractional treatment was limitedly used because it could not control penetration depth and it gave damage on the epidermis.

Recently introduced FRM opens new generation in aesthetic market by meeting the market demand. We observed wound healing process after the FRM treatment in the human body using histological and molecular biology technology. As the result, we found out the fact that FRM treatment induced a strong wound healing response drawing out collagen and

elastin remodeling by Heat Shock Protein (HSPs) expression and various cytokines. Clinical improvement in skin laxity and acne scar is achieved by volume effects produced by neocollagenesis and neoelastogenesis.

STUDY DESIGN AND METHOD

STUDY DESIGN

All subjects consented prior to participation. Patient consent for digital photography and adding the photos in article was also organized prior to treatment. Exclusion criteria consisted of history of injection with silicone, botox, filler, fat or a synthetic material placed in the intended treatment area, hypertrophic scar or bleeding disorder, lidocaine hypersensitivity, photosensitivity or anaphylaxis. Patients with a compromised immune system impaired wound healing, collagen vascular disease, implantable electronic device, or active infection were disqualified from participation. Only subjects consenting to longitudinal follow-up during the study were enrolled.

CLINICAL PROCEDURE

Patients were treated with a minimally-invasive FRM device. Bipolar RF energy was delivered through 49 micro-needle electrodes deployed into the reticular dermis vertically to the skin surface. The epidermis and superficial dermis were protected securely from RF heating at the insertion location by insulating the rest of each electrodes except its distal 0.3mm. Standardized photographs were taken at the baseline and at 3-month follow-up. Follow-up patients were asked to rate their overall satisfaction, the impression of scars and laxity improvement using a five-point scale.

Application Report

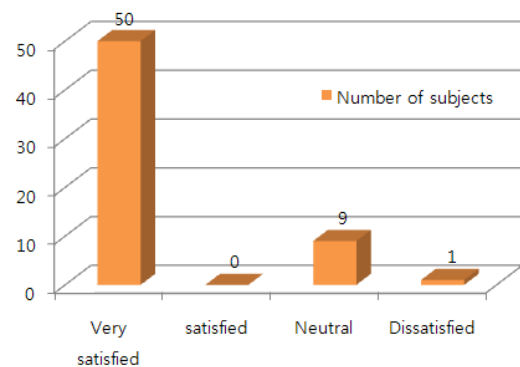


Figure1. FRM patient satisfaction results

TREATMENT RESULTS

60 subjects with mild to significant scar and rhytids were enrolled. All patients received one FRM full face treatment. All subjects were managed for 3 month follow-up. Mean age was 41.2 +/-23.5 years.

All patients experienced transient edema and erythema, but it resolved within 48 hours. 13.3% of the patients experienced dry skin. However it was gone away within 2 weeks. Patient satisfaction was high with 1.6% dissatisfied, 15% neutral, 0% satisfied and 83.3% very satisfied (Fig 1). FRM treatment self assessment of clinical outcome showed significant improvement in acne scar and moderate to significant improvement in skin laxity.

CONCLUSION

FRM treatment has been shown to provide consistent and meaningful improvement in facial scar and laxity without complications and adverse effects. In this study, the average improvement seen following a single FRM treatment was approximately 93.3%. The result of this study may become an important option for scar and facial laxity treatment.

Before and after treatment

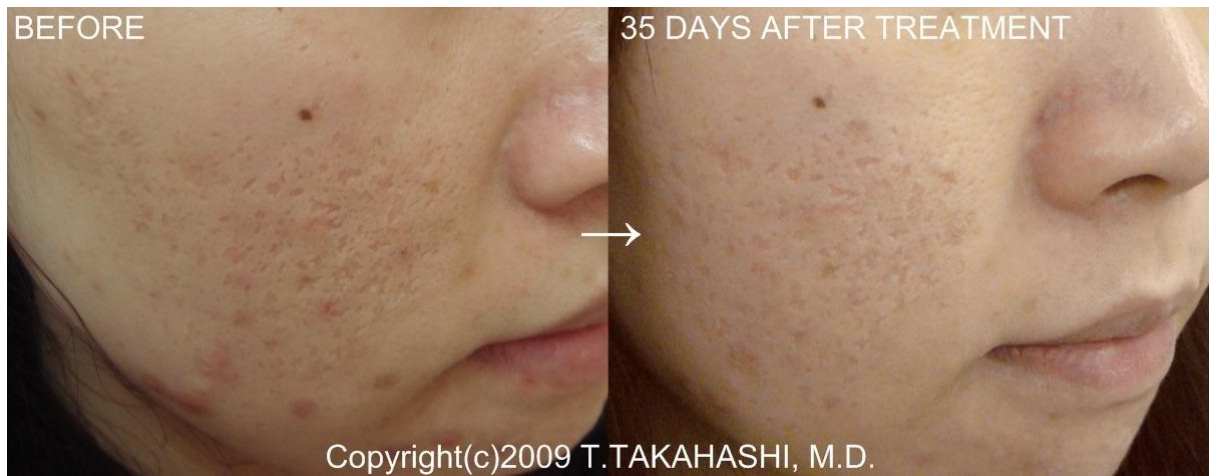

Photo 1

This is a 24 years old female case. After 35 days, rugged area and red keloid of the right face line improved.

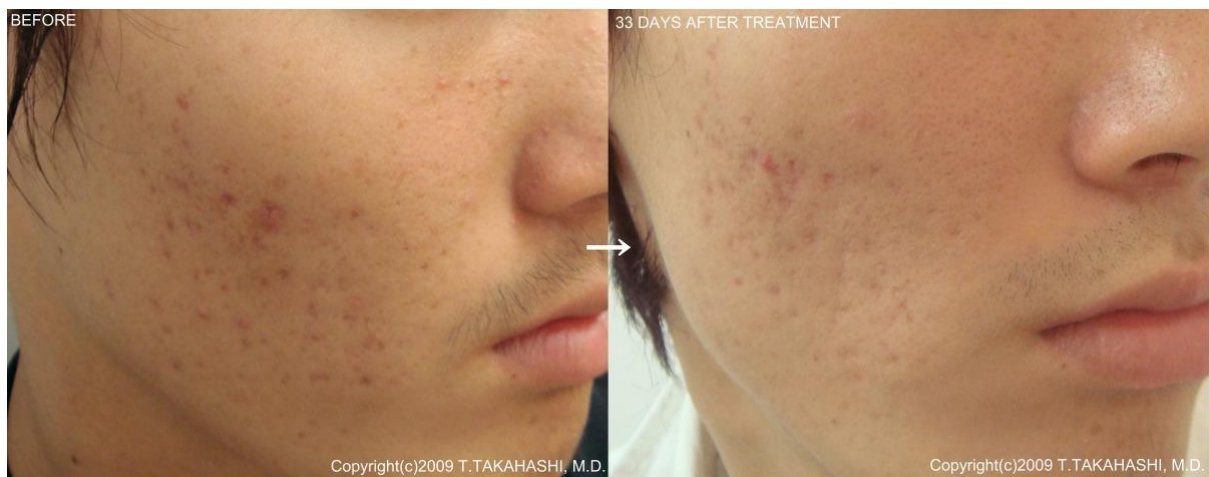

Photo 2

19 years old male patient after 33 days. Red and uneven acne areas improved. Patient testified he did not get acnes.

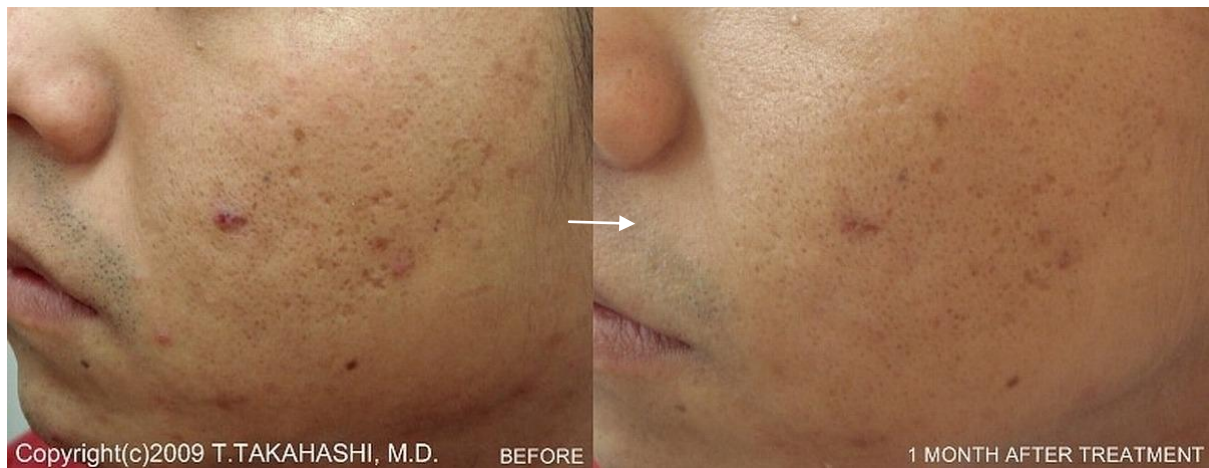Application Report

Photo 3

30 years old male patient. Major symptom was acne and rough uneven face. This is after 1 month. It shows the certain improvement.

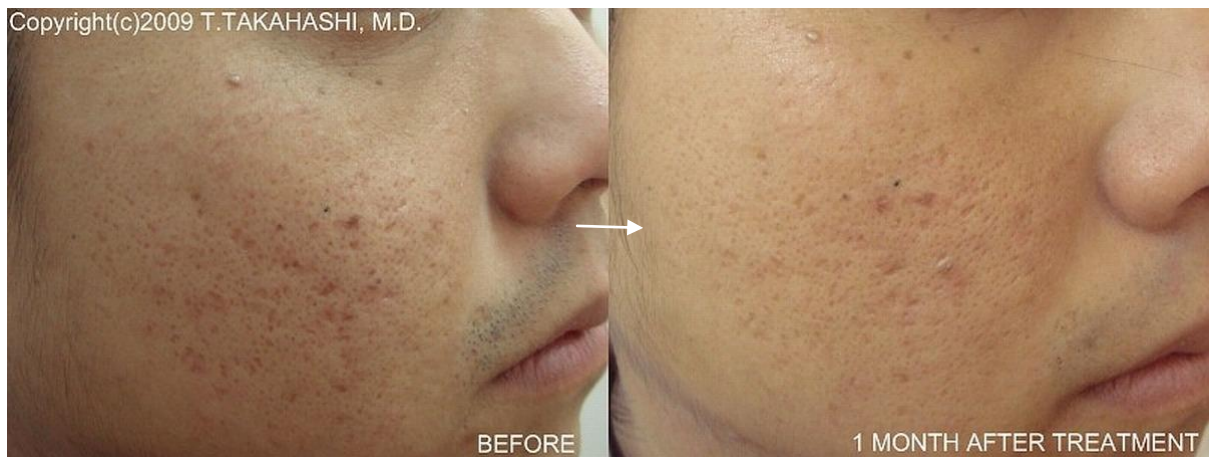

Photo 4

Keloid kind of scar had improved.

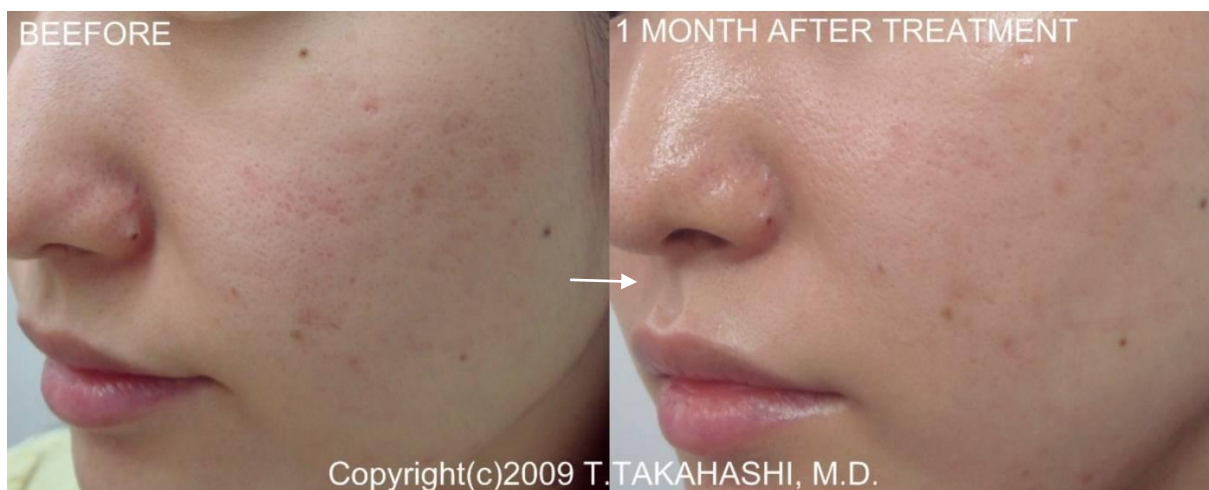

Photo 5

30 years old female patient. Pretty much improved on uneven dented acne scars.

Application Report

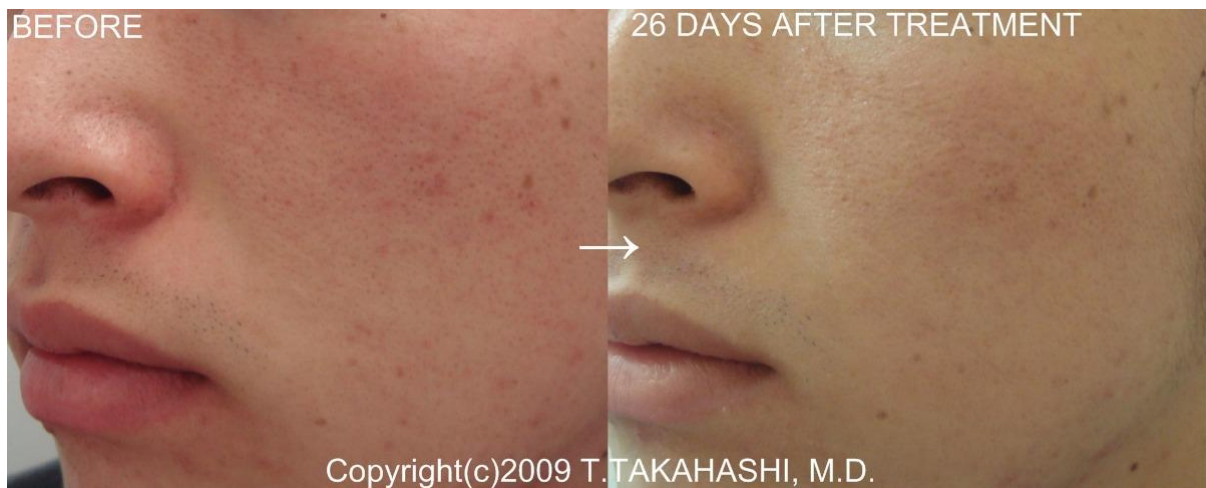

Photo 6

20 years old male patient. Patient testified that his acne and pore had decreased.

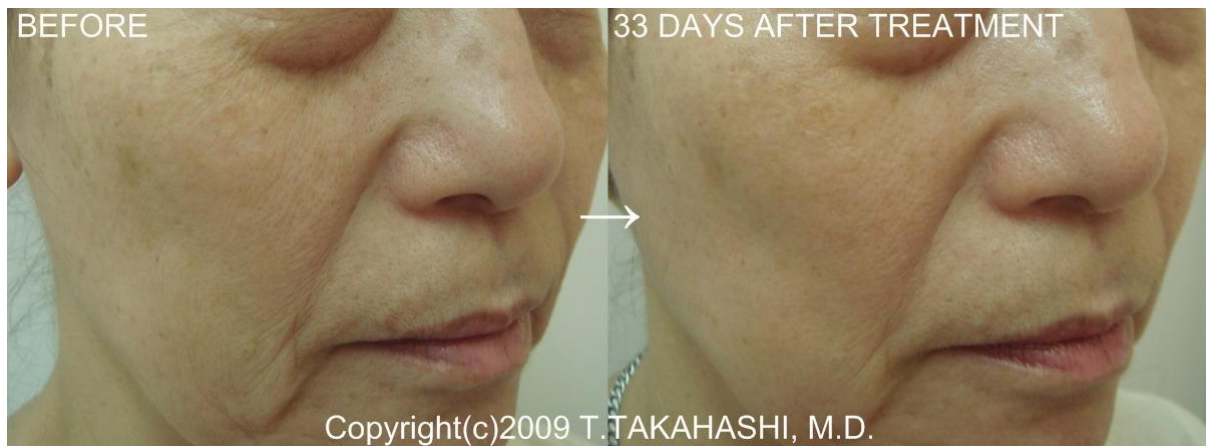

Photo 7

66 years old female patient. Sagged skin and Nasolabial fold had much improved.

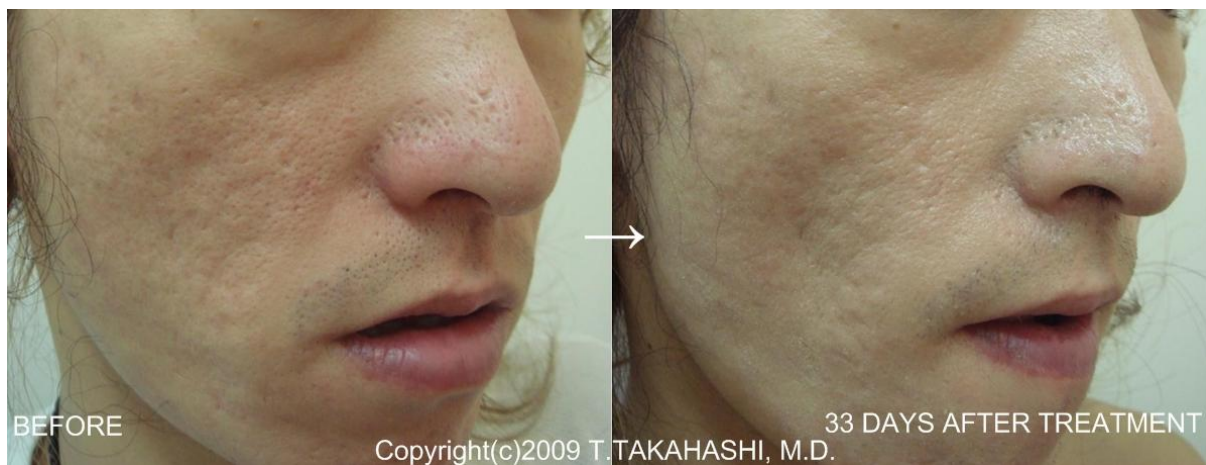

Photo 8

26 years old male patient. After INTRAcel treatment, skin improved as shown in the picture and he was satisfied.

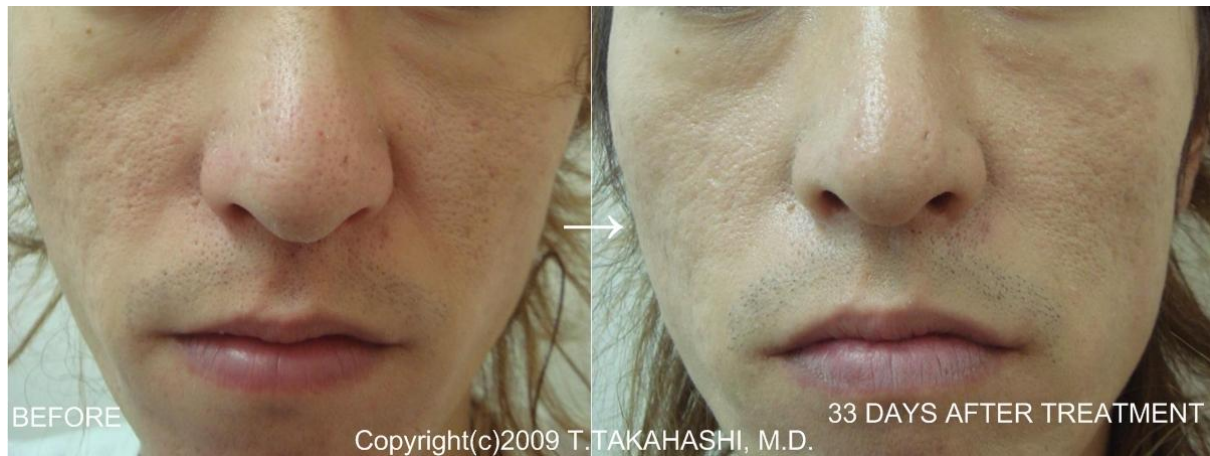Application Report

Photo 9

26 years old male patient. We can see the improvement on his nose, nasolabial area, and sagged skin under the eyes.

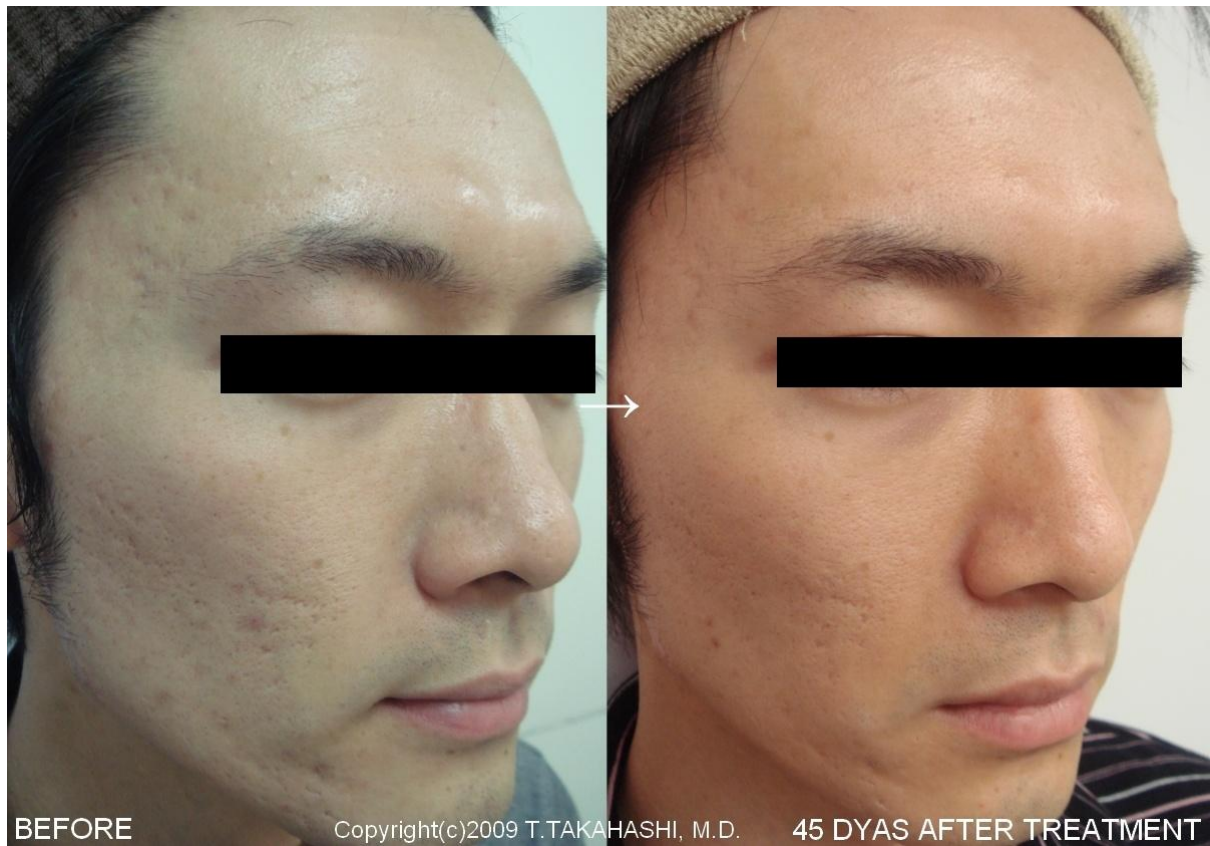

Photo 10

28 years old male patient. Dramatic result has shown on his temple, cheek, and along the face line. Skin improvement had continued after 45 days from the treatment.

Application Report